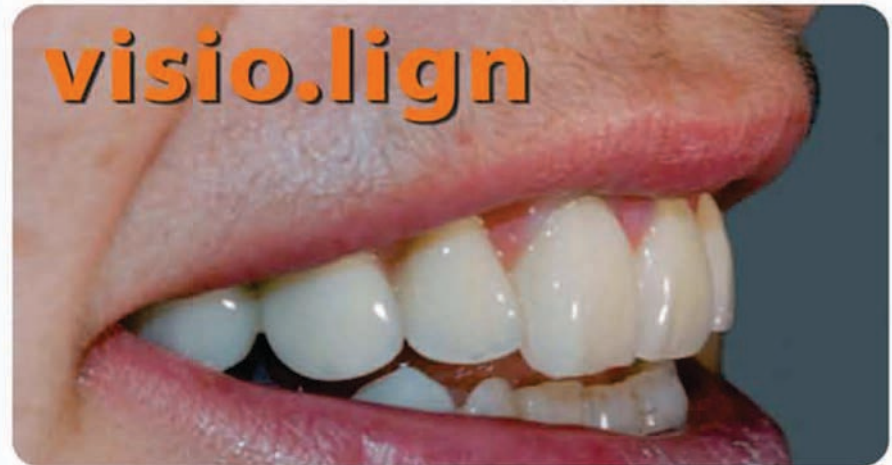
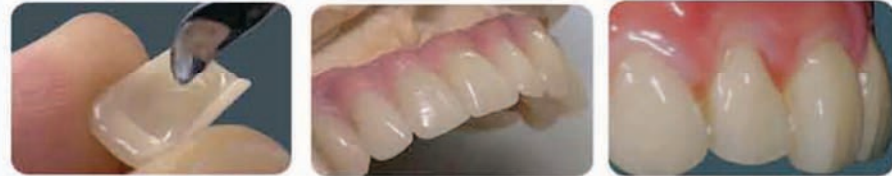
bredent

More than 35 years of dental innovations



PMMA-COMPOSITE VENEERS

PMMA-Composite high impact and abrasion-resistant. Available in anatomical designs for the classic A-D shades. Shape and layering are identical with natural teeth.



FREE Instructional DVD
Call Now! **1.877.328.3965**

visio.lign

Veneering system

bredent
group

Case Study presented at  **Academy of Osseointegration**

26th Annual Meeting

March 3-5, 2011

Washington, D.C.

Visio.Lign Actual Case Study -
two years of experience with
a veneering technique using
veneers based on polymer
material with ceramic filler.



Case study provided by:

K. Merkle, J. de San José González, C. Mertens, H. G. Steveling

Private Practice Gernsbach, Germany

Gonzalez Zahntechnik, Weinheim, Germany

Department of OMF-Surgery, Heidelberg University, Germany,

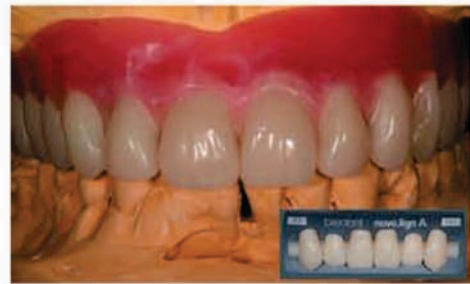Head: Prof. Dr. Dr. J. Hoffmann

Background:

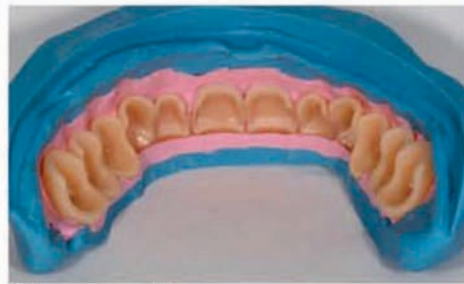In recent years, CAD/CAM technology, in combination with zirconia ceramic, has gained popularity in implant dentistry. Zirconia frameworks and veneering porcelain meet the demands for aesthetic results. However, fractures of the veneering porcelain (chipping) are the most common technical problems. Different reasons seem to be responsible for this phenomenon. Veneers based on a polymer material with ceramic filler seem to avoid these fractures and maintain excellent aesthetic results. The veneering line comprises multi-layer veneers for life-like/anatomical teeth with custom shade characterisation, accessories materials and a bonding system in perfectly matched shades. The cross-linked acrylate ensures resistance to plaque accumulation and the ceramic microfiller, embedded in the polymer matrix, increases the abrasion resistance of this material, which comes very close to that of natural teeth. Occlusal adjustments are easy to perform, so that these restorations can also be used for CMD patients. These veneers can be used for zirconia and metal frameworks.

Method:

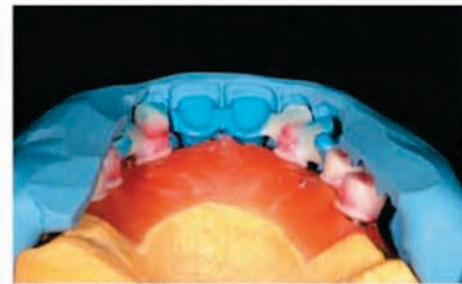
15 patients received implant supported restorations using these veneers (visio.lign, Bredent, Germany). There was one full arch restoration in the maxilla, two full arch restorations in the mandibula, two FPDs (3 units) in the anterior maxilla and ten FPDs (3 units) in the lateral mandibula. Eight FPDs zirconia frameworks were used. The other restorations were made with non precious metal frameworks. All patients had a 3 month control up to two years.



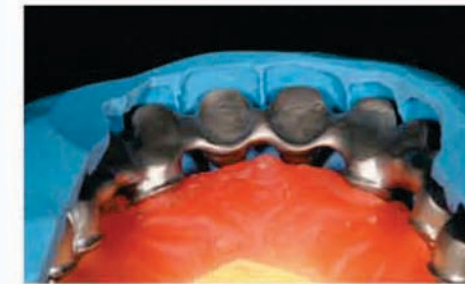
Wax-up with anterior and posterior veneers



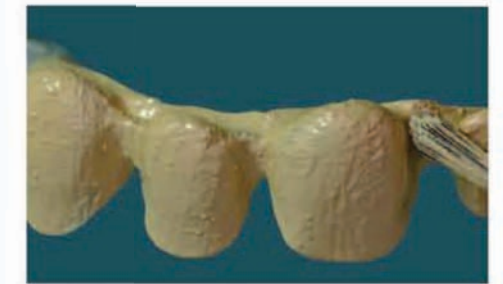Silicone key with veneers



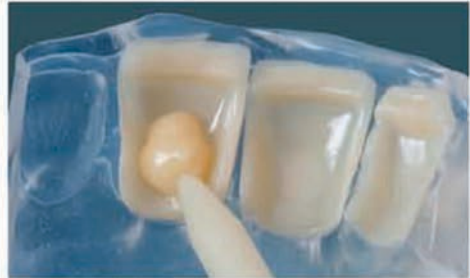Silicone key with wax framework



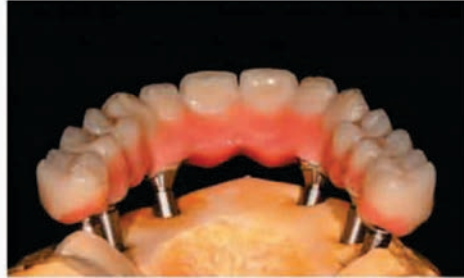Non precious metal framework



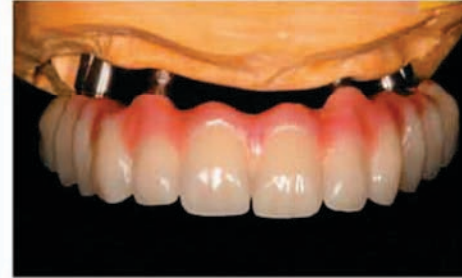Metal framework with opaquer



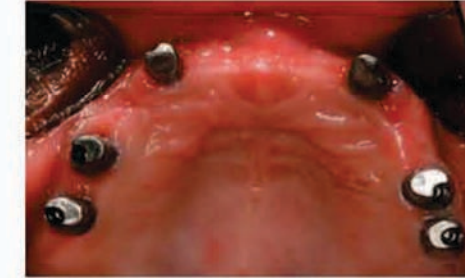Fixation with combo.lign (dual-hardening)



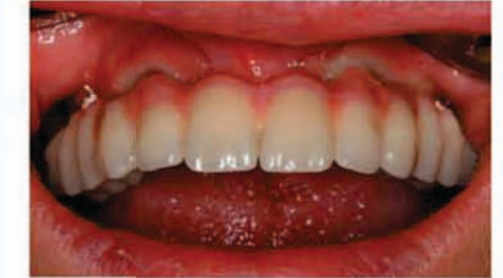Final restoration with pink veneering



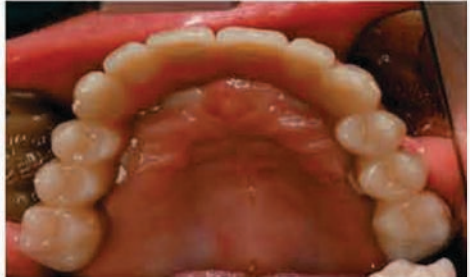Final restoration frontal view



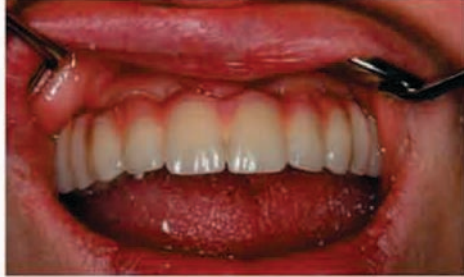Intraoral view with 6 Atlantis abutments



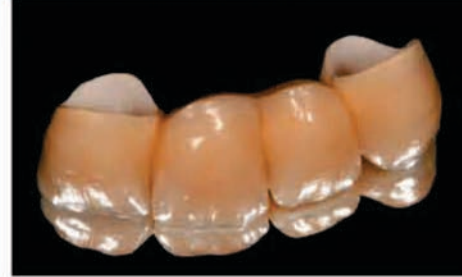Restoration with temporary cement



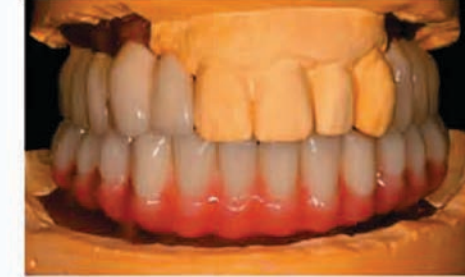Palatal view



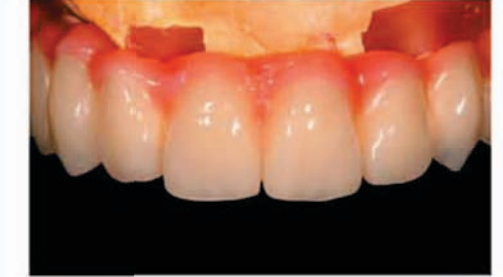After 2 years in function



Example



Example



Example

Results:

The use of this veneering technique in 15 patients with 8 zirconia and 7 non precious metal frameworks with no mechanical problems occurred in a period of two years. There were also no problems with the aesthetic outcome, especially with a discolouration at the edge of the veneers. All patients were satisfied with the aesthetical results and with the chewing comfort.

Conclusion:

Our clinical results justify the further use of this veneering system and seem to be an alternative to the veneering technique with porcelain specially in patients with CMD symptoms.

